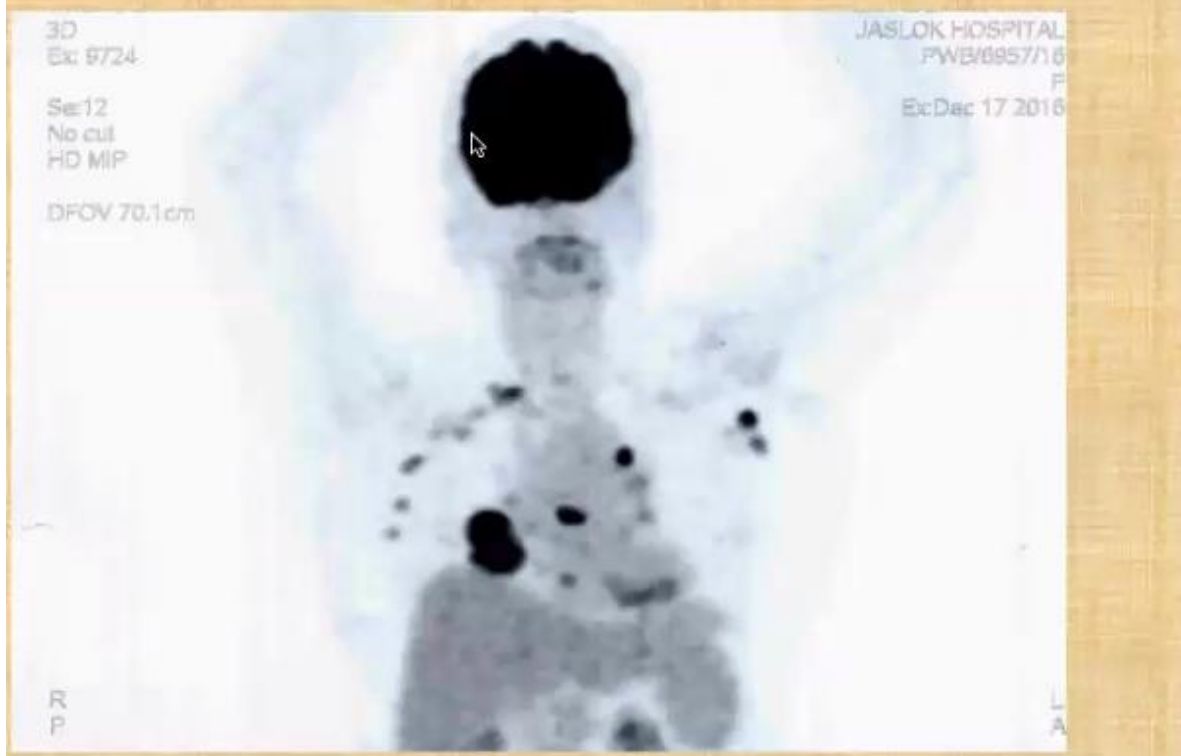

CASE OF 80/F  
**CA Breast with Orbital Metastasis**  
VISIT- DEC 2016

## Before Rx- Scan- 17.12.16



**COMMENTS:** 80 year old female with suspected carcinoma of right breast with orbital metastasis for staging.

Metabolically active right breast lesion as described above is suggestive of primary right breast malignancy.

Metabolically active lesion in left orbit, bilateral axillary, right deep pectoral and right supraclavicular lymph nodes, skeletal lesions and lung nodules are metastatic.

Metabolically active heterogeneously enhancing mass with areas of peripheral calcification in the right adnexa is likely suggestive of right broad ligament fibroid.

No evidence of metabolically active disease anywhere else in the body.

# Chief Complaint

- 80 yrs old woman at present no physical complaint, except difficult movement of left eye
- Left eye has become small in size, vision has not affected, but she cannot do the movement of left eye
- K/C/O - Hypertension, Hyperthyroidism - since 10 years
- DM - 5 years

# Nature

- She describes herself as very independent, like to do things/work as per her wish and will
  - She gets angry too fast if things does not happen as per her will
  - She likes to finish her work before time, till the time she cant rest. She feel relaxed once the work is done
  - She likes to be alone and to take care and help others. she likes to prepare food for others, to look after them. she likes to go out
  - Her daughter describes her as very strict, obstinate, and very dominating
- 
- Even when her husband died, before his death she was taking good care of him, she was preparing food for him what he like. She took about 4 years to come out from the sadness after his death
- 
- In food, she likes fried food





<p><b>Diagnosis</b></p> <p>CA Breast with Orbital Metastasis</p> <p><b>Diagnosis</b></p> <p>CA Breast with Orbital Metastasis</p>	<p><b>Chief Complaint</b></p> <p>Difficult movement of left eye</p> <p>Left eye has became small in size</p> <p>Cannot do movement of left eye</p>	<p><b>Other Complaints</b></p> <p>K/C/O - Hypertension, Thyroid</p> <p>Since 10 years</p> <p>DM - 5 years</p>	<p><b>Nature</b></p> <p>Independent</p> <p>Very strong</p> <p>Takes her own decision</p> <p>Dominating</p>
<p><b>Emotional State</b></p> <p>Loss of Husband, servant</p> <p>Death of close relative</p> <p>Sadness</p> <p>Grief - Silent</p>	<p><b>Anger</b></p> <p>Anger – violent</p> <p>On family</p> <p>Fastidious</p> <p>Impatient – Occupation</p> <p>Hurry, Haste</p>	<p><b>Genius/ Pattern</b></p> <p>She is very strong</p> <p>Independent</p> <p>Takes her own decision</p> <p>Dominating</p> <p>Care, food-nourishment, like a mother</p> <p>She likes babies caring for others</p>	<p><b>Kingdom/ Miasm</b></p> <p>Mineral Kingdom</p> <p>Qualities of 2 different elements</p> <p>-</p> <p>SALT</p>

# On Repertorizing

	Aur-m-n.	Nux-v.	Sep.	Tub.	Nat-m.	Sulph.	Ars.	Ph-ac.	Phos.	Plat.	Thuj.	Bell.	Merc.	Aur.	Plut-n.	Calc.	Kall-c.	Caust.	Staph.	Lach.	Calc-p.
<b>Total Rubrics</b>	12	20	16	16	19	18	19	18	17	17	18	18	15	12	15	15	14	14	13	12	
<b>Kingdoms</b>	12	9	11	8	7	9	8	6	8	8	8	8	8	9	8	7	7	7	8	7	
chest; CANCER; mammae (146)																					
mind; HURRY, haste; occupation, in (68)																					
mind; REPROACHES; ailments from, agg. (140)																					
mind; DICTATORIAL (87)																					
mind; SYMPATHETIC, compassionate, too (164)																					
mind; TRAVEL, desire to (76)																					
mind; DOMINATION by others agg. (62)																					
mind; GRIEF; silent, pent up (150)																					
mind; REMORSE, repentance (118)																					
mind; FASTIDIOUS (105)																					
mind; OBSTINATE, headstrong (208)																					
mind; PLEASE others, desire to (20)																					

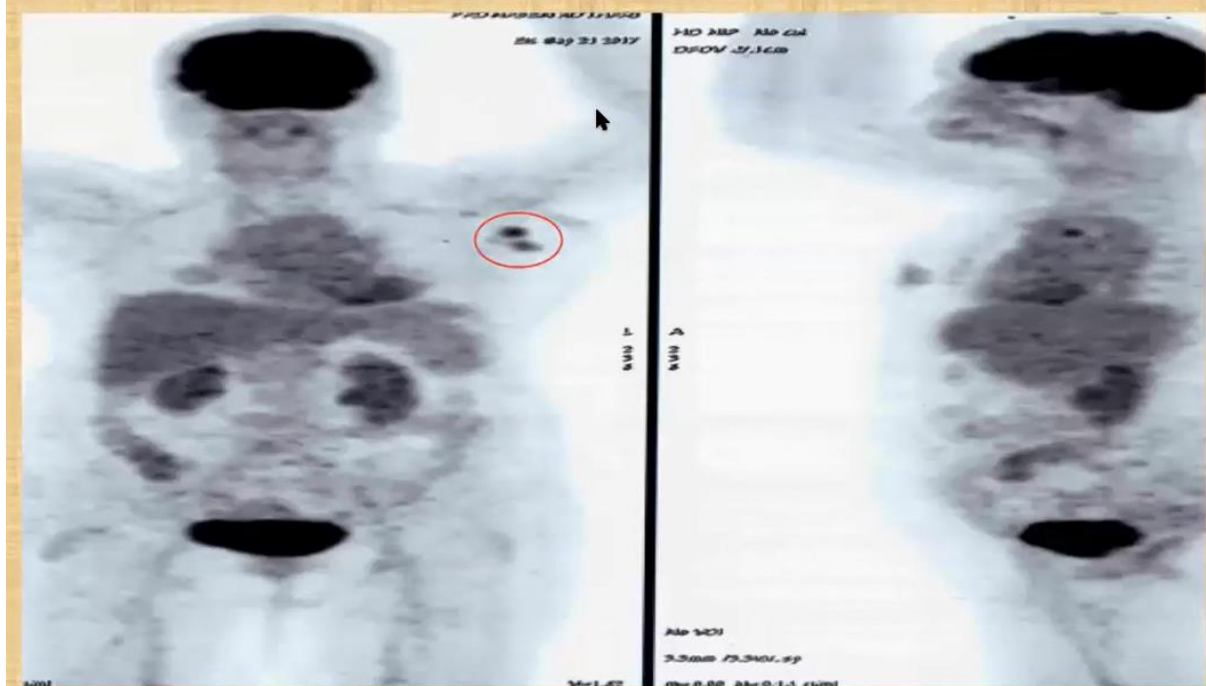
She has qualities of **Aurum** and qualities of **Nat mur**

Aurum	Nat Mur
<ul style="list-style-type: none"> <li>• She is very strong</li> <li>• Independent</li> <li>• Takes her own decision</li> <li>• Dominating</li> <li>• Anger- violent</li> <li>• Anger on family</li> <li>• Fastidious</li> <li>• Occupation –impatient</li> <li>• Hurry-occupation</li> </ul>	<ul style="list-style-type: none"> <li>• Care, food-nourishment, like a mother</li> <li>• She likes babies caring for others</li> <li>• What things affect her emotionally</li> <li>• Loss of the husband/ servant</li> <li>• Death of relative, close</li> <li>• Sadness for 4-5 years</li> <li>• Lot of grief</li> <li>• Silent</li> </ul>

**Remedy Prescribed:**  
**Aurum Mur Natronatum 200 f/b LM6**

pt Padmaben Kothari, Multiple metastatic lesions with malignancy right breast; Aurum m n 200/LM6		
PET/CT scan study	17th dec 16	21st sept 17
left orbital tissue	2.5*2cm	2.6cm*1.4cm
soft tissue mass rt breast	2.9*3.5*4.2cm	2.5cm
	SUV max 13.19	SUV max 3.0
right axillary nodes	1.1*0.8cm, SUV 5	tiny non FDG avid right lymphnode seen
left axillary nodes	1.5*1.5, SUV max 13.19	1.7cm, SUV max 5.9
Right adnexa	6.6*5.6cm, increased FDG intake	5.1*5.8cm, minimal FDG intake,
	Suv max 7	SUVmax 4.0
impression	metabolically active right breast lesion s/o right breast primary malignancy. metabolically active lesion in left orbit, bilateral axillary, right deep pectoral and right supraclavicular LN, skeletal lesions and lung nodules are metastatic. Metabolically active heterogeneously enhancing mass with areas of peripepheral calcification in the right adnexa s/o right broad ligament fibroid.	Hypermetabolic residual rt breast mass with left axillary nodes. residual soft tissue lesion in the left orbit and right adnexa (calcified). non hypermetabolic multiple sclerotic skeletal lesions.
FDG	F-18, Flourodeoxyglucose	
SUV	standard uptake value	

## After Rx- Scan 21.9.17





## Dr. Arvind Kulkarni's Remarks

PET Scan 16.12.2016 } excellent  
17.9.2017 } improvement  
> 80% regression of hot spots  
Excellant response. bone metast  
To continue Homeopathy &

## Follow up- After 1 year OCT 2017

Patient said,

- I am very well. Thank you
- I never wanted to take Allopathy
- I don't have pain, Earlier had pain right mammae, left eye, Now no pain
- I have no problem. Energy is good. Sleep – good. Appetite – good. Feeling ok.
- Now very confident about staying alone in Ahmedabad
- Took Femoral tablet for a month. Didn't suit her, so stopped it.
- According to relatives: Miracle. Doctors had given up. That she would not survive for more. 4<sup>th</sup> stage cancer has improved.
- Rx- Aurum Met 200 f/b LM 6 daily every night for a month.

- 
1. MIND; MORPHINISM, drug addiction; cancerous patients, in (1)
  2. HEAD; CANCER, Forehead; brain; Meningeom (3)
  - \*3. EYE; CANCER (23)
  4. EYE; INFLAMMATION; cancerous (1)
  5. FACE; CANCER; lips; pressure of pipe, from (4)
  - \*6. FACE; CANCER; lips; lower (17)
  - \*7. MOUTH; CANCER (45)
  - \*8. MOUTH; CANCER; Tongue (48)
  - \*9. STOMACH; CANCER (74)
  10. ABDOMEN; CONGESTION; Liver; cancerous patients, in (1)
  11. RECTUM; HEMORRHAGE; anus, from; cancer, with intestinal (1)
  - \*12. FEMALE; CANCER (114)
  13. FEMALE; CANCER; Ovaries (31)
  - \*14. FEMALE; CANCER; Uterus (128)
  15. FEMALE; CANCER; Uterus; grief, after (1)
  16. FEMALE; CANCER; Uterus; mammae, and (1)
  17. FEMALE; CANCER; Uterus; scirrhous (21)
  - \*18. FEMALE; CANCER; Uterus; cervix (48)
  - \*19. CHEST; CANCER; Mammae (105)
  20. CHEST; CANCER; Mammae; scirrhous (25)
  - \*21. GENERALITIES; CANCEROUS affections (235)
  22. GENERALITIES; CANCEROUS affections; anemia, with (1)
  23. GENERALITIES; ULCERS; cancerous (35)

Kommentar ca:

der aur-m-n Fall ist schön; konstit. tatsächlich aur und nat-m Anteile dazu die Tatsache, dass aur-m-n ein Riesen KRebsmittel ist (s. die Krebs-Rubriken oben. Besonders interessant und zum Fall passend:

Krebs Augen

Krebs Mamma und Uterus 1/1 (denn dort hatte sie eine Meta s. PET Bild)